

Side-Viewing Duodenoscope versus Forward-Viewing Gastroscope for Endoscopic Retrograde Cholangiopancreatography in Billroth II Gastrectomy Patients

Inês Marques de Sá^a Carlos Borges Chaves^b João Correia de Sousa^c
João Fernandes^b Tarcísio Araújo^b Jorge Canena^{d,e} Luís Lopes^{b,f,g}

^aDepartment of Gastroenterology, Portuguese Oncology Institute of Porto, Porto, Portugal; ^bDepartment of Gastroenterology, Hospital Santa Luzia, Viana do Castelo, Portugal; ^cDepartment of Gastroenterology, Hospital das Forças Armadas, Porto, Portugal; ^dDepartment of Gastroenterology, Professor Doutor Fernando Fonseca Hospital, Amadora, Portugal; ^eDepartment of Gastroenterology, Nova Medical School-Faculty of Medical Sciences, Lisbon, Portugal; ^fLife and Health Sciences Research Institute (ICVS), School of Medicine, University of Minho, Braga, Portugal; ^gICVS/3B's - PT Government Associate Laboratory, Braga/Guimarães, Portugal

Keywords

Endoscopic retrograde cholangiopancreatography · Billroth II operation · Gastroscope · Duodenoscope

Abstract

Introduction: Endoscopic retrograde cholangiopancreatography (ERCP) in patients with Billroth II gastrectomy is still a challenging procedure. The optimal approach, namely the type of endoscope and sphincter management, has yet to be defined. **Aim:** To compare the efficacy and safety of forward-viewing gastroscopes and the side-viewing duodenoscopes in ERCP of patients with Billroth II gastrectomy. **Methods:** We conducted a retrospective, single-center cohort study of consecutive patients with Billroth II gastrectomy submitted to ERCP in an expert center for ERCP between 2005 and 2021. The outcomes assessed were: papilla identification, deep biliary cannulation, and adverse events (AEs). Multivariate analysis was performed to evaluate potential associations and predictors of the main outcomes. **Results:** We included 83 patients with a median age of 73 (IQR 65–81) years. ERCP was performed using side-viewing duodenoscope in 52 and for-

ward-viewing gastroscopes in 31 patients. Patients' characteristics were similar in the two groups. The global rate of papilla identification was 66% ($n = 55$). The rate of deep cannulation was 58% considering all patients and 87% in the subgroup of patients in which the papilla major was identified. Cannulation was performed with standard methods in 65% of cases and with needle-knife fistulotomy in 35%. AEs occurred in 4 patients. There was no difference between duodenoscope and gastroscopes in papilla identification (64% [95% CI: 51–77] vs. 71% [55–87]). Although not statistically significant, duodenoscope had a lower deep cannulation rate when considering all patients (52% [15–39] vs. 68% [7–35]) and a higher AEs rate (8% [1–15] vs. 0% [0–1]). In a multivariate analysis, the use of gastroscopes significantly increased the deep cannulation rate (OR = 152.62 [2.5–9,283.6]). **Conclusion:** This study demonstrates that forward-viewing gastroscopes are at least as effective and safe as side-viewing duodenoscopes for ERCP in patients with Billroth II gastrectomy. Moreover, our study showed that gastroscopes are an independent predictor of successful cannulation.

© 2022 Sociedade Portuguesa de Gastrenterologia.
Published by S. Karger AG, Basel

Colangiopancreatografia retrógrada endoscópica em doentes com gastrectomia com reconstrução Billroth II: duodenoscópio ou gastroscópio de visão frontal?

Palavras Chave

Colangiopancreatografia retrógrada endoscópica · Cirurgia Billroth II · Gastroscópio · Duodenoscópio

Resumo

Introdução: Colangiopancreatografia retrógrada endoscópica (CPRE) em doentes submetidos previamente a gastrectomia com reconstrução Billroth II é ainda um exame desafiante. A melhor abordagem, nomeadamente o tipo de endoscópio e a técnica de canulação biliar, ainda não está definida. **Objetivo:** Comparar a eficácia e segurança do gastroscópio de visão frontal e do duodenoscópio de visão lateral na CPRE de doentes com gastrectomia com reconstrução Billroth II. **Métodos:** Conduzimos um estudo de coorte retrospectivo e unicêntrico que incluiu consecutivamente doentes com gastrectomia com reconstrução Billroth II submetidos a CPRE num centro de referência para CPRE entre 2005 e 2021. Os outcomes avaliados foram: identificação da papila, canulação biliar profunda e efeitos adversos (EAs). Regressão logística foi realizada para avaliar possíveis associações e preditores dos outcomes. **Resultados:** Incluímos 83 doentes com uma idade mediana de 73 (IIQ 65–81) anos. A CPRE foi realizada usando duodenoscópio em 52 doentes e usando o gastroscópio de visão frontal em 31 doentes. As características dos doentes foram semelhantes entre os dois grupos. A taxa global de identificação da papila foi de 66% ($n = 55$). A taxa de canulação profunda foi de 58% considerando todos os doentes e de 87% considerando apenas o subgrupo de doentes nos quais a papila major foi identificada. A canulação foi realizada usando métodos convencionais em 65% e usando fistulotomia com faca em 35% dos doentes. EAs ocorreram em 4 doentes. Não houve diferenças entre duodenoscópio e gastroscópio relativamente à identificação da papila [64% (95% CI: 51–77) vs 71% (55–87)]. Apesar de estatisticamente não significativo, o uso de duodenoscópio teve uma menor taxa de canulação profunda quando considerados todos os doentes [52% (15–39) vs 68% (7–35)] e uma maior taxa de EAs [8% (1–15) vs 0% (0–1)]. Na regressão logística, o uso de gastroscópio significativamente aumentou a taxa de canulação profunda [OR = 152.62 (2.5–9,283.6)]. **Conclusão:** Este estudo demonstra que o uso de gastroscópio de visão frontal é

pelo menos igualmente eficaz e seguro ao duodenoscópio na CPRE de doentes com gastrectomia com reconstrução Billroth II. Para além disso, o nosso estudo demonstrou que o uso de gastroscópio é um predictor independente para canulação.

© 2022 Sociedade Portuguesa de Gastroenterologia.
Published by S. Karger AG, Basel

Introduction

Endoscopic retrograde cholangiopancreatography (ERCP) in patients with Billroth II gastrectomy is still a challenging procedure due to altered anatomy, even among experienced endoscopists. ERCP in patients with Billroth II gastrectomy is technically more demanding, with ERCP failures associated with afferent loop intubation, papilla identification, deep biliary cannulation in an inverted papilla, and performance of sphincterotomy [1–4]. Moreover, it presents more risks than ERCP performed in patients with normal anatomy, with perforation rates of up to 2.8% [1].

Different endoscopes may be used, including side-viewing duodenoscope, forward-viewing gastroscope (with or without cap-fitting) [4, 5], balloon-assisted enteroscope [6, 7], colonoscope [8], and anterior oblique-viewing endoscope [9]. While papilla identification and cannulation are thought to be easier with side-viewing duodenoscope; afferent loop intubation and reaching the papilla are easier with forward-viewing gastroscope with lower risk of perforation [1, 4, 10]. Regarding cannulation, different cannulation techniques have been described: standard cannulas, conventional sphincterotome [3, 8, 11], needle-knife [8, 11], and rotatable or dedicated inverted sphincterotome [11, 12]. However, the optimal approach, namely the type of endoscope and sphincter management, has yet to be defined. Indeed, comparative studies are scarce [10, 11] and the majority of the studies published are retrospective, without prospective databases, and single arm [1, 3, 4, 7, 12].

Therefore, we aim to compare the efficacy and safety, as well as their determinants, of performing ERCP using forward-viewing gastroscope versus duodenoscope in patients with Billroth II gastrectomy.

Methods

Study Design, Setting, and Selection of Participants

We conducted a retrospective, single-center cohort study including all consecutive patients with Billroth II gastrectomy and

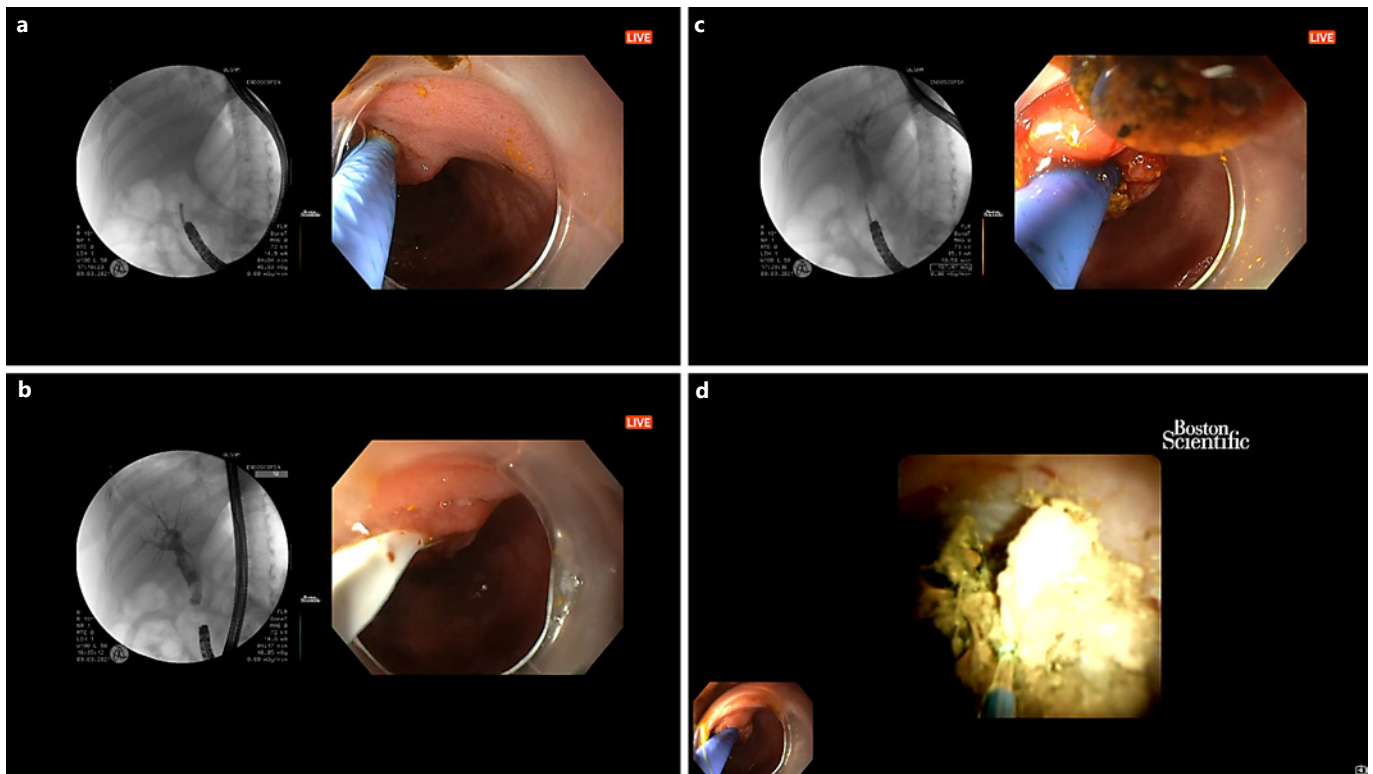


Fig. 1. Endoscopic retrograde cholangiopancreatography performed with a forward-viewing gastroscop with cap. **a** Cannulation. **b** Stone extraction. **c** Cholangiogram. **d** Cholangioscopy-guided laser lithotripsy.

native papilla submitted to ERCP between January 2005 and March 2021 at Hospital Santa Luzia, ULSAM, Viana do Castelo, Portugal; a hospital affiliated with the School of Medicine, University of Minho, a referral center for advanced biliopancreatic endoscopy. We included only ERCP for management of biliary disease.

ERCP Procedures

Written informed consent was obtained from all patients. ERCPs were performed by two experienced endoscopists (L.L. and J.R.) who each performed ≥ 300 ERCPs annually for the past 15 years. All ERCPs were performed under deep sedation/general anesthesia with propofol (by an anesthesiologist). ERCP was always started with the patient in the prone position. If intubation of the afferent loop was not feasible, the patient was turned to left lateral decubitus, to facilitate entering the afferent loop. The afferent loop intubation was confirmed by the presence of bile and by the endoscope position on fluoroscopy. The afferent loop was intubated with minimal air/CO₂ insufflation, and most papillae were located at the 10- or 11-o'clock position. Deep cannulation was initially attempted using a standard straight catheter (Triple Lumen ERCP cannula, Tapered Tip 5.5 Fr; Boston Scientific, Natick, MA, USA), attempting to insert the catheter gently into the bile duct; if deep insertion was not feasible, after minimal insertion of the catheter in the ampulla (1–2 mm), the guidewire was carefully advanced into the common biliary duct (CBD) under fluoroscopy. Pushing the catheter against the duodenal wall at the 9- to 10-o'clock position or changing the position of the tip of the endoscope led the tip

of the catheter to the correct access to the CBD. We used a 0.035-inch hydrophilic guide wire (Jagwire; Boston Scientific). If deep cannulation was not achieved, needle-knife fistulotomy (NKF) was performed as a second-line approach, using an Olympus KD-11Q, Olympus Corporation, Melville, NY, USA). After successful biliary cannulation, if sphincterotomy was indicated, a 5-cm plastic biliary stent was inserted, and an NKF was performed in the 5-o'clock direction over the plastic biliary stent placed along the bile duct. Once the ERCP was completed, all patients were admitted to the inpatient area of the hospital and observed for 24 h, before discharge. When deep cannulation of the bile duct was unsuccessful after NKF, a second ERCP was scheduled in less than a week.

All procedures were performed using a forward-viewing gastroscop or a duodenoscope (Olympus TJF 160 VR, GIF-Q165, GIF-1TH190; Olympus Corporation). Between 2005 and 2015 all ERCPs were performed exclusively with a side-viewing duodenoscope. Taking into account new-evidence-based literature [13, 14] and practice experience, after 2015 all ERCP procedures were always performed using a forward-viewing gastroscop (Fig. 1). All ERCPs performed with a forward-viewing were initially attempted without a cap (Transparent cap Olympus D-201-11804); a cap was attached to the tip of the forward-viewing gastroscop only in cases where cannulation was unsuccessful. In case of failure with either duodenoscope (2005–2015) or gastroscop (2015–2021), there was no attempt to perform ERCP with another endoscope.

Table 1. Patient characteristics and ERCP data according to endoscope type

	All (n = 83)	Side-viewing duodenoscope (n = 52)	Forward-viewing gastroscope (n = 31)	p
Age, years (IQR)	73 (65–81)	74 (65–83)	73 (67–79)	0.992
Male, n (%)	56 (68)	36 (69)	20 (65)	0.809
ERCP indications, n (%)				0.061
Cholelithiasis	34 (41)	18 (35)	16 (52)	
Biliary stenosis	31 (37)	19 (37)	12 (39)	
Unspecific dilation of biliary tract	11 (13)	10 (19)	1 (3)	
Biliary leak	2 (2)	2 (4)	0 (0)	
Papilla identification, n (%)	55 (66)	33 (64)	22 (71)	0.632
Main reasons for failed papilla identification, n (%)				0.619
Acute angulation of the anastomosis	12 (43)	7 (37)	5 (56)	
Long afferent loop	11 (33)	8 (42)	3 (33)	
Food debris	2 (7)	2 (11)	0 (0)	
Papilla not identified	2 (7)	1 (5)	1 (11)	
Deep cannulation, n (%)	48 (57)	27 (52)	21 (68)	0.176
Method of cannulation, n (%)				0.769
Standard methods	31 (65)	18 (67)	13 (62)	
Fistulotomy	17 (35)	9 (33)	8 (38)	
Sphincterotomy	27 (33)	16 (31)	11 (36)	0.809
Plastic/metal stent, n (%)	28/4 (39)	13/1 (27)	15/3 (58)	0.006
Cholangioscopy, n (%)	3 (4)	0 (0)	3 (10)	0.049
ERCP diagnosis, n (%)				0.173
Cholelithiasis	21 (25)	9 (17)	12 (39)	
Malignant stenosis	17 (20)	9 (17)	8 (26)	
Unexplained biliary dilatation	4 (5)	4 (8)	0 (0)	
Benign stenosis	2 (2)	1 (2)	1 (3)	
Complications, n (%)				0.147
Perforation	3 (4)	3 (6)	0 (0)	
Hemorrhage	1 (1)	1 (2)	0 (0)	

Data Collection, Variables and Outcomes

Data was collected from a dedicated prospectively maintained database. Data on demographic variables, year of the procedure, ERCP indication and diagnosis, type of endoscope, biliary access technique, therapeutic interventions, complications and its management were extracted from the database. The complications were reported by severity and time of occurrence (intra-procedural, early [within 14 days of follow-up] and late [after 14 days of follow-up]) according to ASGE lexicon's severity grading system [15]. The two primary outcomes evaluated were: (1) success rate of papilla major identification and (2) deep biliary cannulation. The success rate of biliary cannulation is presented for all patients (intention-to-treat), as well as for the subgroup of patients in which the papilla major was identified. The secondary outcomes were: (3) rate of ERCP-related adverse events and (4) evaluation of reasons for not identifying the papilla major. The ERCP-related adverse events are presented for all patients (inten-

tion-to-treat) as well as for the subgroup of patients in which the papilla major was identified.

Statistical Analysis

Descriptive statistics included mean and standard deviation or median and interquartile range (IQR) for quantitative variables and proportions for categorical variables. The differences in baseline characteristics between the two endoscope groups was assessed using the Student *t* test for age and the χ^2 test (with Bonferroni adjustment for multiple comparisons) for categorical variables. The association between endoscope and quantitative variables was analyzed using the *t* test or the corresponding non-parametric test. The association between endoscope and categorical variables was analyzed with the χ^2 test (with Bonferroni adjustment for multiple comparisons). Multiple logistic regressions were performed to evaluate predictors of the main outcomes. In the multivariable regression model, we included variables that physi-

Table 2. Potential factors affecting papilla cannulation: multivariate analysis

	OR (95% CI)	<i>p</i> value
Year of ERCP	0.55 (0.32–0.97)	0.4
ERCP indication	3.21 (0.24–42.4)	0.88
Endoscope	152.62 (2.51–9 283.56)	0.02

ologically could be associated with the outcome or variables with a *p* value less than 0.25 in simple regression model. The 95% CIs were calculated and used to compare the results between endoscope groups. A *p* value of <0.05 was considered statistically significant.

Results

Patient Characteristics and ERCP Indications

We included 83 patients with a median age of 73 (IQR 65–81) years; 68% of them were male. The main indications for ERCP were choledocholithiasis (41%), biliary stenosis (37%), nonspecific dilation of biliary tract (13%), and biliary leak (2%). ERCP was performed using a side-viewing duodenoscope in 52 patients and a forward-viewing therapeutic gastroscope in 31 patients. There were no differences between endoscope groups regarding patient characteristics (duodenoscope vs. gastroscope: age, 74 [IQR 65–83] vs. 73 [IQR 67–79] years, *p* = 0.992; male, 69 vs. 65%, *p* = 0.809) (Table 1).

Primary Outcomes

Access to the papilla was achieved in 66% of patients (*n* = 55), of which 93% (*n* = 51) in the first ERCP. The rate of deep cannulation was 58% (48/83) in all patients (intention-to-treat analysis) and 87% (48/55) in the subgroup of patients in which the papilla major was identified, with 88% (*n* = 42) cannulated at the first ERCP. Cannulation was achieved using standard methods in 65% (*n* = 31) of cases (with sphincterotomy performed in 27 patients) or with NKF in 35% (*n* = 17) of cases. Cholangioscopy with the Spyglass system was performed in 3 cases, of which 2 underwent cholangioscopy-guided laser lithotripsy. Of the patients that underwent papilla cannulation, a biliary stent was inserted after cannulation in 66% (*n* = 32) when indicated (plastic stent in 28 and metallic stent in 4) (Table 1).

There was no difference between side-viewing duodenoscope and forward-viewing gastroscope in papilla identification rate (64% [95% CI: 51–77] vs. 71% [55–87],

p = 0.632). Although not statistically significant, side-viewing duodenoscope had a lower deep cannulation rate than forward-viewing gastroscope when considering all patients (52% [15–39] vs. 68% [7–35], *p* = 0.176) and when considering only the subgroup of patients in which the papilla major was identified (82% [72–92] vs. 95% [89–100], *p* = 0.223).

Secondary Outcomes

Adverse events occurred in 4 patients: 3 perforations in the anastomosis (all intra-procedural and severe) and 1 hemorrhage (intra-procedural and moderate) (Table 1).

When considering all patients, duodenoscope had a higher adverse events rate (8% [1–15] vs. 0% [0–0.5], *p* = 0.147) namely perforation (*p* = 1.0) and hemorrhage rate (*p* = 1.0), though not statistically significant. Likewise, when considering only the subgroup of patients in which the papilla major was identified and biliary cannulation attempted, duodenoscope had a higher adverse events rate (9% [0–18] vs. 0% [0–1], *p* = 0.208), though not statistically significant.

There was failure to identify the papilla in 34% of cases (*n* = 28) due to (i) acute angulation of the anastomosis in 43% (*n* = 12); (ii) long afferent loop in 39% (*n* = 11) of cases; (iii) food debris in 7% (*n* = 2); (iv) papilla not identified despite afferent loop exploration in 7% (*n* = 2); and (v) anesthesia-related complication in 4% of cases (*n* = 1).

Multiple Logistic Regression

There was no significant time trend regarding papilla identification (*p* = 0.256), deep cannulation (*p* = 0.779) and adverse events (*p* = 0.962). In a univariate analysis, there was no significant interaction between time of ERCP and type of endoscope used regarding papilla identification (*p* = 0.763), deep cannulation (*p* = 0.16) and adverse events (*p* = 0.763). In a multivariate analysis, the use of gastroscope significantly increased the cannulation rate [OR = 152.62 (95% CI = 2.5–9,283.6), *p* = 0.02] when controlling for year of ERCP and ERCP indication (Table 2). However, the type of endoscope was not associated with papilla identification or with risk of perforation (Tables 3, 4).

Discussion

ERCP in patients with Billroth II gastrectomy has various challenges that have to be overcome. Firstly, recognition and intubation of the afferent loop, sometimes ham-

Table 3. Potential factors affecting papilla identification: multivariate analysis

	OR (95% CI)	<i>p</i> value
Year of ERCP	1.07 (0.91–1.27)	0.41
ERCP indication	1.54 (0.52–4.55)	0.99
Endoscope	1.01 (0.19–5.25)	0.99

Table 4. Potential factors affecting perforation: multivariate analysis

	OR (95% CI)	<i>p</i> value
Year of ERCP	1.22 (0.79–1.87)	0.36
Endoscope	0.001 (0.001–1.0)	0.99
Cannulation	5.68 (0.44–74.01)	0.19
Sphincterotomy	0.001 (0.001–1.0)	0.99

pered by acute angulation of the anastomosis. Then, progression on the afferent loop and papilla identification can also be hampered because of angulations, adhesions or long afferent loop. After reaching the papilla, cannulation maneuvers have to be adapted to the inverted position of the endoscope. Therefore, ERCP in patients with Billroth II gastrectomy is still a challenging procedure [2, 16].

Although the side-viewing duodenoscope is the most commonly used endoscope for ERCP in Billroth II gastrectomy patients, forward-viewing gastroscope has been increasingly used. However, each endoscope has its advantages and drawbacks. While papilla identification and cannulation are thought to be easier with side-viewing duodenoscope due to its elevator and large working channel; afferent loop intubation and reaching the papilla are easier with forward-viewing gastroscope with consequently lower risk of perforation [1, 2, 4, 10]. Although the choice of endoscope has been a matter of controversy, there is still lack of comparative studies regarding ERCP in patients with Billroth II gastrectomy. Indeed, Park and Song [1] conducted a recent systematic review showing that there is only 1 retrospective and 1 prospective comparative study about the choice of endoscope [10, 17]. Besides these two comparative studies, 3 retrospective cohorts have been published reporting the use of forward- and side-viewing endoscope in ERCP in patients with Billroth II gastrectomy [3, 8, 18]. In this systematic review, the overall rate of papilla cannulation was 87.9%, and the overall rate of adverse events rate was 7.3%. When

analyzed by endoscope, the success rate of papilla cannulation was 95.3% for side-viewing endoscope and 95.2% for forward-viewing endoscope. Moreover, the authors demonstrated that the rate of perforation was slightly higher in side-viewing endoscope (3.6%) compared with forward-viewing endoscope (1.7%) [1]. Likewise, we found that the use of forward-viewing gastroscope significantly increased the deep cannulation rate in a multivariate analysis. Although the type of endoscope was not associated with the risk of perforation in a multivariate analysis, the risk of perforation was higher with side-viewing duodenoscope (6%) compared with forward-viewing gastroscope (0%). Recently, Nennstiel et al. [19] published the daily clinical management of patients with altered anatomy and the need of biliary intervention in four tertiary endoscopic centers in Munich. In 33 patients with Billroth II that underwent ERCP with gastroscope, the success rate (defined as reaching the papilla with successful cannulation) was 79%, with 71% of cases with unsuccessful papilla identification and 29% with unsuccessful papilla cannulation. In 72 patients with Billroth II that underwent ERCP with duodenoscope, the success rate was 86%, with 50% of cases with unsuccessful papilla identification and 50% with unsuccessful papilla cannulation [19].

In our study, the favorable results of forward-viewing gastroscope in comparison to the side-viewing duodenoscope can result from the fact that we used a therapeutic gastroscope with an extra-large channel associated sometimes with a transparent cap fitted to the distal end, facilitating not only afferent loop intubation and progression due to its flexibility and good visual field, but also deep cannulation due to its large working channel and use of cap. Recently, two retrospective cohorts of 18 and 46 patients with Billroth II gastrectomy that underwent ERCP using therapeutic double-channel gastroscope reported afferent loop intubation of 83% and papilla cannulation of 100% [20, 21].

This study has some limitations. It is a single-center retrospective cohort with no randomized allocation of the type of endoscope which can lead to bias. Another possible limitation is the sample size, which can influence the effect size, especially in the subgroup analysis. Indeed, the non-statistically significant lower adverse events rate with the forward-viewing gastroscope may traduce the small sample size. However, the majority of the studies published to date have smaller sample sizes [7, 8, 10, 11, 19–21]. Moreover, this study was performed in a tertiary referral center with expertise in ERCP, which could have positively impacted the results, stressing the need to refer

these patients to expert centers. In our study, before 2015, all ERCPs were performed with a side-viewing duodenoscope and after 2015, all ERCP were performed with a forward-viewing gastroscope. This change of type of endoscope in 2015 resulted from a discretionary decision of the endoscopy team and evidence-based literature [13] in order to improve the safety of the intubation of the afferent limb. Therefore, we conducted a multivariate analysis that excluded any significant impact of time on papilla identification, deep cannulation, or adverse events suggesting that the favorable results of forward-viewing gastroscope were not due to experience of the endoscopist but rather due to the type of endoscope used.

Besides the side-viewing duodenoscope and forward-viewing gastroscope (with or without cap-fitting), other endoscopes and techniques have been studied in surgically altered anatomy according to centers experience and technique availability, namely balloon-assisted enteroscope [6, 7], colonoscope [8], anterior oblique-viewing endoscope [9], endoscopic ultrasonography-guided transhepatic antegrade interventions [22], and underwater cap-assisted ERCP [23]. Future comparative studies are warranted.

Although Billroth II anatomy will become less frequent, we will encounter these patients in our endoscopic practice, and we will have to face the challenges to safely and successfully perform ERCP [2]. Current data and this study demonstrate that therapeutic forward-viewing gastroscope with cap-fitting, when necessary, is at least as effective and as safe as side-viewing duodenoscope for ERCP in patients with Billroth II gastrectomy. However,

future multi-center randomized trials with large sample size are needed to validate these results and to define the optimal endoscopic approach.

Statement of Ethics

The study was approved by the Ethical Committee of Hospital Santa Luzia, Unidade Local de Saúde Alto Minho, Viana do Castelo, Portugal.

Conflict of Interest Statement

The authors declare no conflicts of interest.

Funding Sources

No funding or supporting source to declare.

Author Contributions

Carlos Borges Chaves, João Sousa, Tarcísio Araújo, João Fernandes, Luís Lopes – data collection; Inês Marques de Sá – data analysis and drafting the manuscript; Tarcísio Araújo, Jorge Canena, Luís Lopes – review of the article.

Data Availability Statement

Data available on request.

References

- 1 Park TY, Song TJ. Recent advances in endoscopic retrograde cholangiopancreatography in Billroth II gastrectomy patients: a systematic review. *World J Gastroenterol*. 2019;25:3091–107.
- 2 Easler JJ, Sherman S. Cap-assisted pancreaticobiliary endoscopy in Billroth II anatomy: ERCP “through the looking glass. *Gastrointest Endosc*. 2016;83:1202–4.
- 3 Bove V, Tringali A, Familiari P, Gigante G, Boškoski I, Perri V, et al. ERCP in patients with prior Billroth II gastrectomy: report of 30 years’ experience. *Endoscopy*. 2015;47:611–6.
- 4 Park TY, Kang JS, Song TJ, Lee SS, Lee H, Choi JS, et al. Outcomes of ERCP in Billroth II gastrectomy patients. *Gastrointest Endosc*. 2016;83:1193–201.
- 5 Park CH, Lee WS, Joo YE, Kim HS, Choi SK, Rew JS. Cap-assisted ERCP in patients with a Billroth II gastrectomy. *Gastrointest Endosc*. 2007;66:612–5.
- 6 Chu YC, Su SJ, Yang CC, Yeh YH, Chen CH, Yueh SK. ERCP plus papillotomy by use of double-balloon enteroscopy after Billroth II gastrectomy. *Gastrointest Endosc*. 2007;66:1234–6.
- 7 Itoi T, Ishii K, Sofuni A, Itokawa F, Tsuchiya T, Kurihara T, et al. Single-balloon enteroscopy-assisted ERCP in patients with Billroth II gastrectomy or Roux-en-Y anastomosis (with video). *Am J Gastroenterol*. 2010;105:93–9.
- 8 Wang F, Xu B, Li Q, Zhang X, Jiang G, Ge X, et al. Endoscopic retrograde cholangiopancreatography in patients with surgically altered anatomy: one single center’s experience. *Medicine*. 2016;95:e5743.
- 9 Law NM, Freeman ML. ERCP by using a prototype oblique-viewing endoscope in patients with surgically altered anatomy. *Gastrointest Endosc*. 2004;59:724–8.
- 10 Kim MH, Lee SK, Lee MH, Myung SJ, Yoo BM, Seo DW, et al. Endoscopic retrograde cholangiopancreatography and needle-knife sphincterotomy in patients with Billroth II gastrectomy: a comparative study of the forward-viewing endoscope and the side-viewing duodenoscope. *Endoscopy*. 1997;29:82–5.
- 11 Coşkun O, Ödemiş B. A comparative study of side-viewing duodenoscope and forward-viewing gastroscope to perform endoscopic retrograde cholangiopancreatography in patients with Billroth II gastrectomy. *Surg Endosc*. 2021;35:4222–30.

- 12 Kim GH, Kang DH, Song GA, Heo J, Park CH, Ha TI, et al. Endoscopic removal of bile-duct stones by using a rotatable papillotome and a large-balloon dilator in patients with a Billroth II gastrectomy (with video). *Gastrointest Endosc*. 2008;67:1134–8.
- 13 Ki HS, Park CH, Jun CH, Park SY, Kim HS, Choi SK, et al. Feasibility of cap-assisted endoscopic retrograde cholangiopancreatography in patients with altered gastrointestinal anatomy. *Gut Liver*. 2015;9:109–12.
- 14 Jang JS, Lee S, Lee HS, Yeon MH, Han J-H, Yoon SM, et al. Efficacy and safety of endoscopic papillary balloon dilation using cap-fitted forward-viewing endoscope in patients who underwent Billroth II gastrectomy. *Clin Endosc*. 2015;48:421–7.
- 15 Cotton PB, Eisen GM, Aabakken L, Baron TH, Hutter MM, Jacobson BC, et al. A lexicon for endoscopic adverse events: report of an ASGE workshop. *Gastrointest Endosc*. 2010;71:446–54.
- 16 Pribadi RR, Rani AA, Abdullah M. Challenges of endoscopic retrograde cholangiopancreatography in patients with Billroth II gastrointestinal anatomy: a review article. *J Dig Dis*. 2019;20:631–5.
- 17 Kawamura T, Mandai K, Uno K, Yasuda K. Does single-balloon enteroscopy contribute to successful endoscopic retrograde cholangiopancreatography in patients with surgically altered gastrointestinal anatomy? *ISRN Gastroenterol*. 2013;2013:214958.
- 18 Itoi T, Ishii K, Itokawa F, Kurihara T, Sofuni A. Large balloon papillary dilation for removal of bile duct stones in patients who have undergone a billroth ii gastrectomy. *Dig Endosc*. 2010;22:S98–102.
- 19 Nennstiel S, Freivogel K, Faber A, Schlag C, Haller B, Blöching M, et al. Endoscopic and percutaneous biliary interventions in patients with altered upper gastrointestinal anatomy: the Munich Multicenter Experience. *Surg Endosc*. 2021;35(12):6853–64.
- 20 Wang S, Liu W, Sun S, Wang G, Liu X, Ge N, et al. Clinical evaluation of double-channel gastroscope for endoscopic retrograde cholangiopancreatography in patients with Billroth II gastrectomy. *Prz Gastroenterol*. 2016;11:163–9.
- 21 Yao W, Huang Y, Chang H, Li K, Huang X. Endoscopic retrograde cholangiopancreatography using a dual-lumen endogastroscope for patients with Billroth II gastrectomy. *Gastroenterol Res Pract*. 2013;2013:146867.
- 22 Itoi T, Sofuni A, Tsuchiya T, Ijima M, Iwashita T. Endoscopic ultrasonography-guided transhepatic antegrade stone removal in patients with surgically altered anatomy: case series and technical review (with videos). *J Hepatobiliary Pancreat Sci*. 2014;21(12):E86–93.
- 23 Fugazza A, Anderloni A, Paduano D, Badalamenti M, Maselli R, Carrara S, et al. Underwater cap-assisted endoscopic retrograde cholangiopancreatography in patients with surgically altered anatomy: a pilot study. *Endoscopy*. 2021;53(9):927–31.